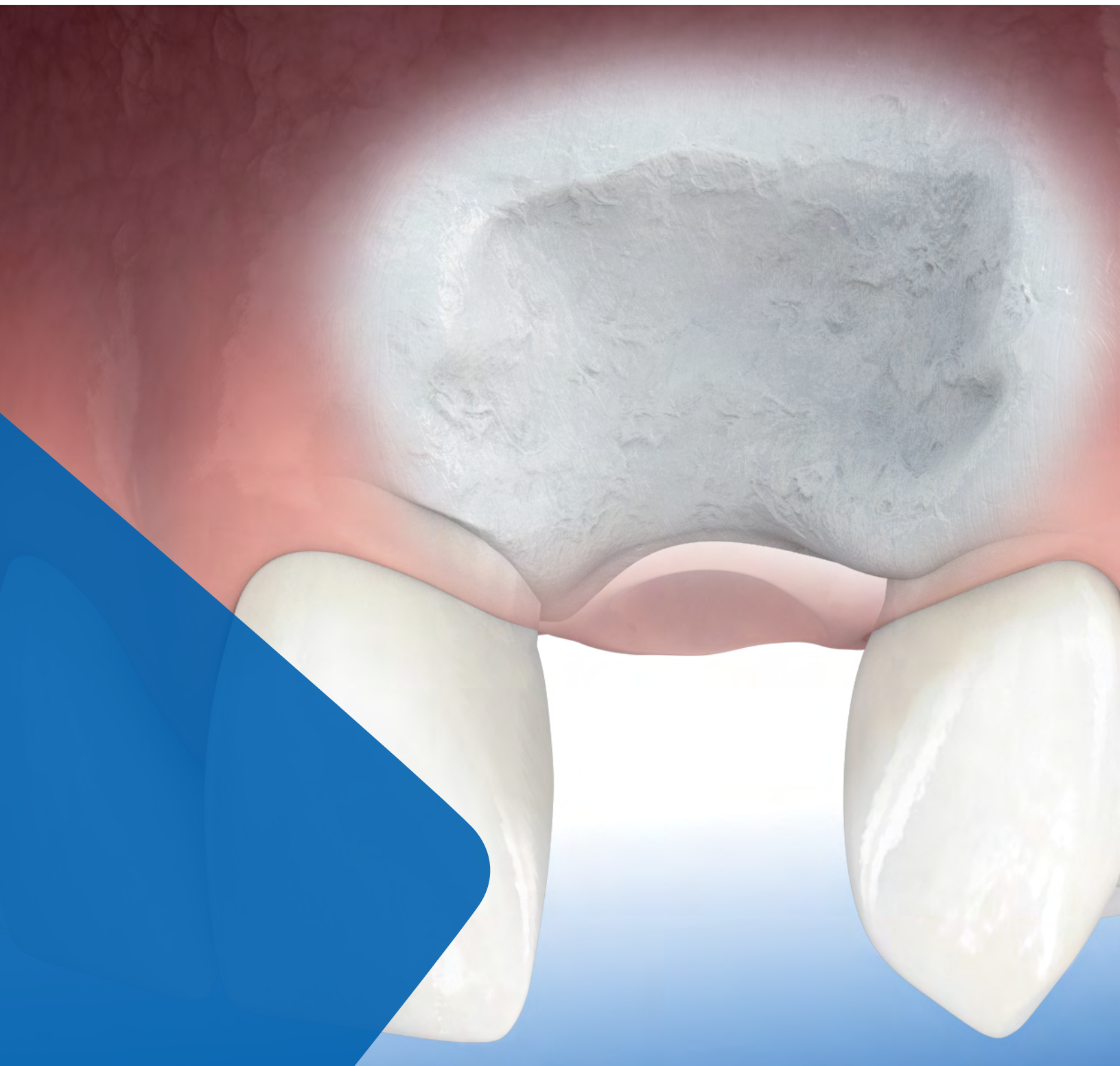

LEADING REGENERATION

Geistlich
Biomaterials

Major Bone Augmentation



Overview

Due to its osteoinductive potential, autologous bone is the gold standard for major bone augmentation procedures. It is very effective in stimulating new bone formation in large-scale defects. But human bone grafts are subject to a certain amount of resorption, which may affect the long-term clinical success of the therapy.

Geistlich biomaterials optimally complements human bone. Thanks to its high resorption stability and osteoconductivity, Geistlich Bio-Oss® protects human bone grafts against degradation. Geistlich Bio-Gide® a native collagen membrane provides a barrier function long enough to protect the newly forming bone from soft-tissue ingrowth and provides support for wound healing.

Advantages of Utilizing Geistlich Biomaterials

Higher Patient Satisfaction¹⁻⁹

- › Less invasive surgery
- › Fewer complications
- › Lower morbidity

Stable Clinical Outcome¹⁰⁻¹⁴

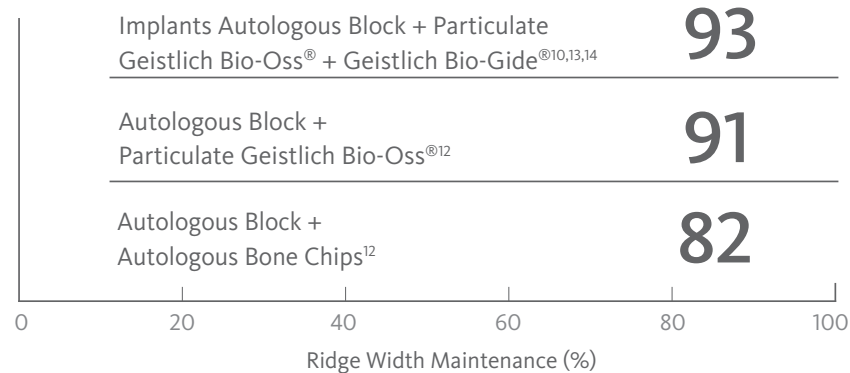
- › Less bone resorption

Long-term Implant Survival Rate^{3,7,8}

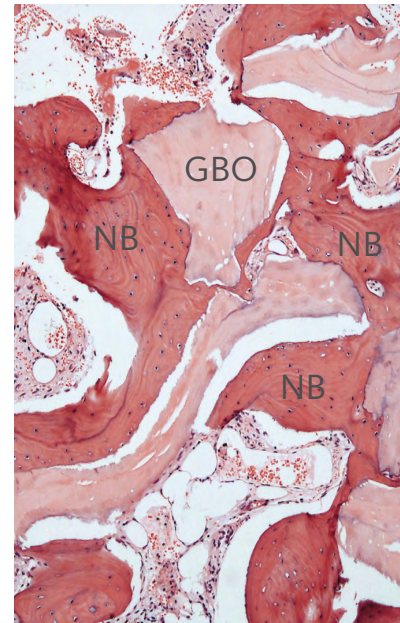
- › Predictable bone gain



A Powerful Combination with Geistlich Bio-Oss® and Geistlich Bio-Gide®



New Bone Formation with Geistlich Biomaterials



Decalcified Histology
New bone (NB) formation surrounding Geistlich Bio-Oss® particles (GBO)

“Human bone grafts are subject to unwanted resorption. Therefore, we always combine Geistlich biomaterials with autologous bone for larger augmentations.”

Prof. Dr. István Urbán

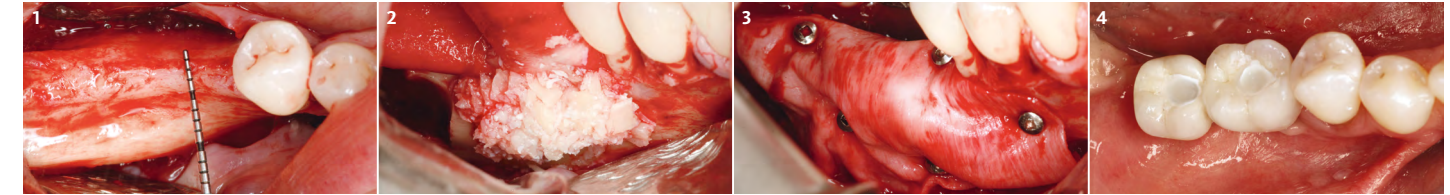
Case Documentation

Horizontal Ridge Augmentation Utilizing the Sausage Technique

Prof. Dr. István Urbán, Budapest, Hungary

Objectives

- › The aim of this procedure is to predictably develop optimal bone width for dental implant placement with a technique which has minimal morbidity and more patient satisfaction



1 Occlusal view of the thin posterior mandibular ridge. A full thickness, mid-crestal incision is used in the keratinized gingiva. For surgical access, the two divergent vertical incisions are placed, one at the mesio-buccal line angle of the first premolar and an oblique vertical incision was created at the most distal aspect of the crestal incision.

2 Buccal view after application of a 1:1 mixture of autologous particulated bone and Geistlich Bio-Oss® granules. Note that the Geistlich Bio-Gide® membrane is secured on the crest before the application of the graft.

3 Buccal view of a single Geistlich Bio-Gide® membrane, which is fixed with titanium pins. The pins are 1 mm diameter, which are stable in the cortical bone of the mandible. Note that the fixated membrane completely immobilizes the bone graft creating the sausage skin effect.

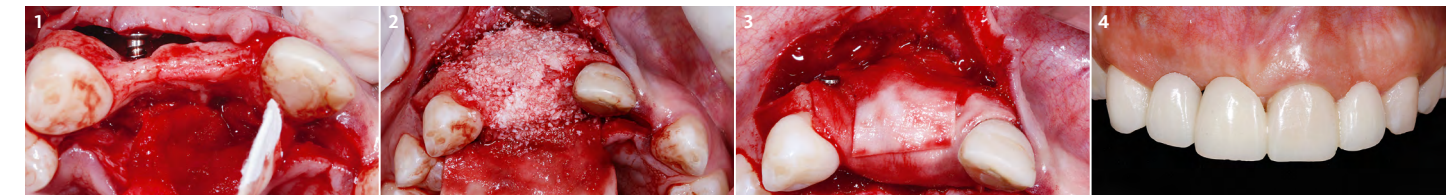
4 Final outcome 2 years after implant loading.

Horizontal Augmentation Using Geistlich Bio-Gide® and Particulate Bone Graft

Prof. Dr. Robert Carvalho da Silva, Prof. Dr. Paulo Fernando Mesquita, Prof. Dr. Julio Cesar Joly, Sao Paulo, Brazil

Objectives

- › Horizontal alveolar ridge augmentation with Geistlich Bio-Oss® and Geistlich Bio-Gide®
- › Minimizing autologous bone harvesting and resorption protection



1 Intra-operative view of the atrophied anterior maxillary site. Tenting screws are placed to support and stabilize the Geistlich Bio-Gide® membrane.

2 A 1:1 mixture of autologous bone chips from the retromolar area and Geistlich Bio-Oss® is applied.

3 Coverage utilizing a dual layer of Geistlich Bio-Gide®.

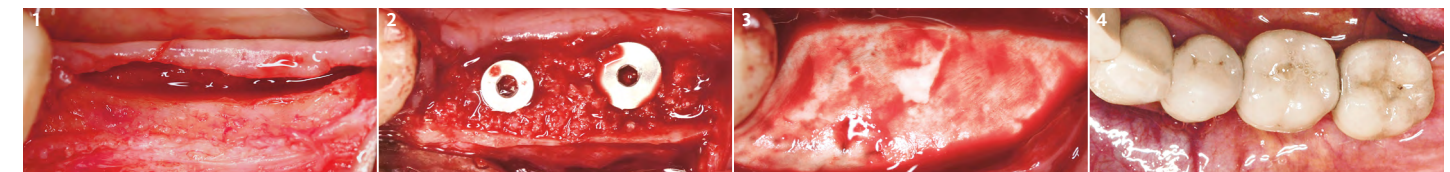
4 Final prosthetic restoration.

Crest Splitting

Dr. Gerhard Iglhaut, Filderstadt, Germany

Objectives

- › Crest splitting procedure in combination with Geistlich Bio-Oss® and Geistlich Bio-Gide® for horizontal augmentation
- › Preservation of the alveolar ridge volume



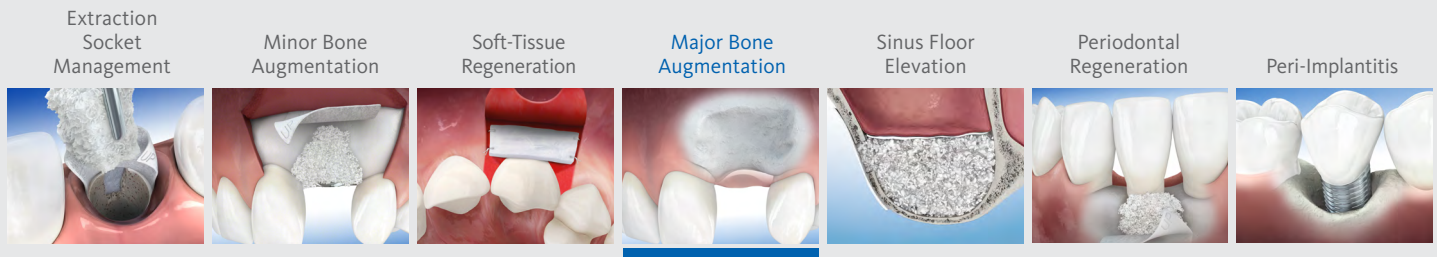
1 Occlusal view of the ridge following flap elevation.

2 The split around the implants is filled with a 1:1 mixture of autologous bone chips from the retromolar area and Geistlich Bio-Oss®.

3 The augmented ridge is covered with Geistlich Bio-Gide® prior to closing of the soft-tissue.

4 Occlusal view of the prosthetic outcome.

For additional information on [Major Bone Augmentation](#), please visit the dental professional section of our website: www.geistlich-na.com



Therapeutic Areas

At Geistlich Biomaterials, we are committed to developing treatments that are uniquely matched to the clinical situations you see every day. That's why we do more than bring you a family of products – we provide proven solutions in specific therapeutic areas.

The recommended Geistlich products below are the ideal biomaterials for use in **Major Bone Augmentation** procedures.

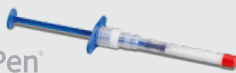Recommended Products for Major Bone Augmentation

BONE SUBSTITUTES

Geistlich
Bio-Oss



Geistlich
Bio-Oss Pen



Geistlich
Bio-OssCollagen



MEMBRANES

Geistlich
Bio-Gide



The Ideal Geistlich Biomaterials for Major Bone Augmentation

When used in combination, these proven and reliable products provide a foundation for long-term clinical success in regenerative dentistry.

Geistlich Bio-Oss® provides a stable scaffold for bone formation leading to long-term volume preservation, while Geistlich Bio-Gide® ensures undisturbed bone regeneration and prevents soft-tissue ingrowth.

For additional information about Major Bone Augmentation, please visit the Dental Professional section of our website: www.geistlich-na.com

CAUTION: Federal law restricts these devices to sale by or on the order of a dentist or physician.

For information on indications, contraindications, precautions, and directions for use, please refer to the Geistlich Bio-Oss®, Geistlich Bio-Oss Collagen® and Geistlich Bio-Gide® Instructions for Use at: www.geistlich-na.com/ifu

Geistlich Pharma North America, Inc.
202 Carnegie Center
Princeton, NJ 08540
Customer Care Toll-free: 855-799-5500
info@geistlich-na.com
www.geistlich-na.com

- Li, J. et al. (2013). *Implant Dent.* 22(2): 112-6.
- Felice, P. et al. (2009). *Clin Oral Implants Res.* 20(12): 1386-93.
- Urban, IA. et al. (2013). *Int J Periodontics Restorative Dent.* 33(3): 299-307.
- Merli, M. et al. (2013). *Int J Periodontics Restorative Dent.* 33(2): 129-36.
- De Santis, D. et al. (2012). *J Craniofac Surg.* 23(3): 186-9.
- Trevisiol, L. et al. (2012). *J Cariofac Surg.* 23(5): 1343-8.
- Chiapasco, M. et al. (2013). *Clin Oral Implants Res.* 24(6): 679-87.
- Jung, RE. et al. (2013). *Clin Oral Implants Res.* 24(10): 1065-73.
- Schwarz, F. et al. (2008). *Clin Oral Implants Res.* 19(4): 402-15.
- von Arx, T. et al. (2006). *Clin Oral Implants Res.* 17(4): 359-66.
- Canullo, L. et al. (2006). *Int J Periodontics Restorative Dent.* 26(4):355-61.
- Maiorana, C. et al. (2005). *Int J Periodontics Restorative Dent.* 25(1): 19-25.
- Maiorana, C. et al. (2011). *Open Dent J.* 25(5): 71-8.
- Cordaro, L. et al. (2011). *Clin Oral Implants Res.* 22(10): 1145-50.
- Kim, M. et al. (2008). *In Vivo.* 22(2): 231-6.
- Reddy, KP. et al. (2006). *J Contemp Dent Pract.* 7(1): 60-70.
- Tal, H. et al. (2008). *Clin Oral Implants Res.* 19(3): 295-302.