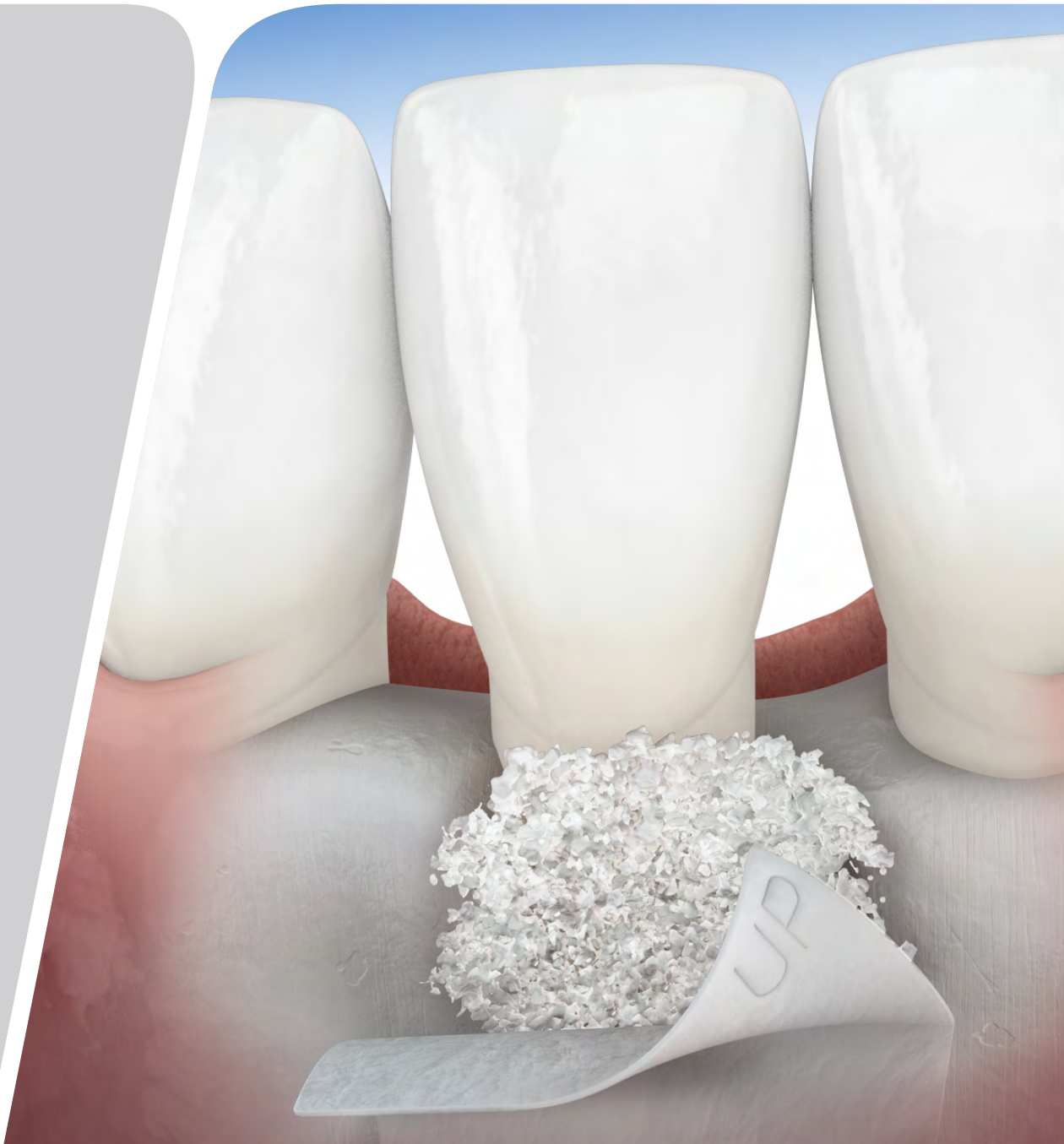

Treatment Solutions for

PERIODONTAL REGENERATION



LEADING REGENERATION

OVERVIEW

Every dentist aims to improve and restore proper function and esthetics in patients affected by periodontitis. Accordingly, it has been argued that periodontally compromised teeth should be treated for as long as possible, and should only be extracted when periodontal and endodontic treatment is no longer possible.^{1,2}

The extraction of teeth affected by periodontitis will not resolve the underlying host response-related problems contributing to the disease. Moreover, periodontally compromised but treated teeth are known to have survival rates equal to the survival rates of implants in well-maintained patients.³

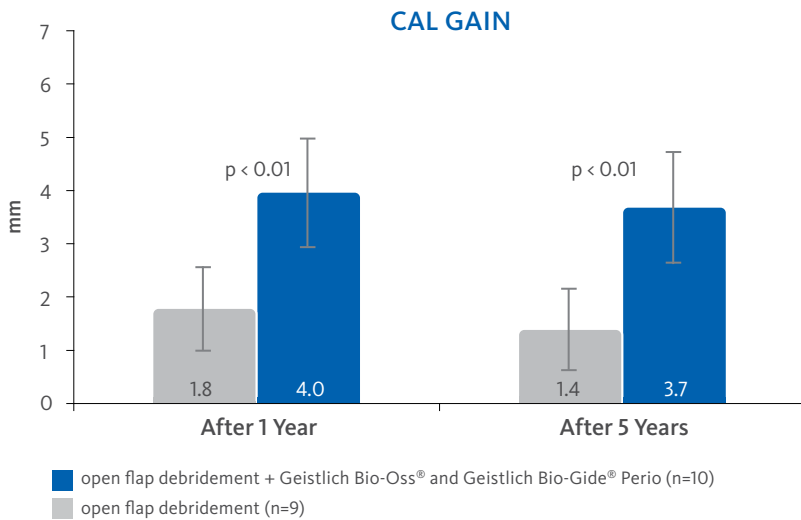
Aims of Regenerative Treatment

- Restoration of the complete tooth attachment apparatus with bone, cementum and periodontal ligament
- Prevention of long junctional epithelial downgrowth as a risk factor for recurrence of periodontitis
- Long-term tooth retention
- Excellent appearance

Guided Tissue Regeneration

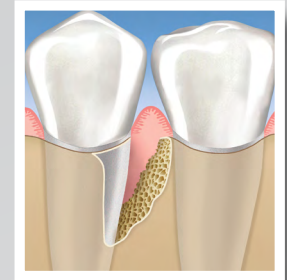It has been shown that carefully selected biomaterials used with proven treatment protocols may not only stop progression of periodontal disease, but effectively regenerate both hard and soft-tissue.^{4,5}

Some evidence shows that the combined filling of periodontal defects with the graft material Geistlich Bio-Oss Collagen® or Geistlich Bio-Oss® followed by coverage with a Geistlich Bio-Gide® membrane has a history of proven effectiveness in regenerative periodontal therapy.⁶⁻¹²

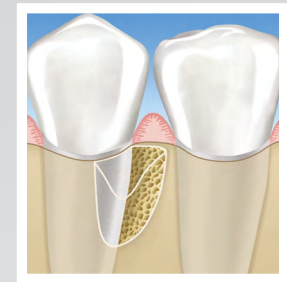

The gain in clinical attachment level (CAL) and the reduction in pocket depth (PD) are significantly larger in the test group than in the control group respectively, ($p=0.01$ and ≤ 0.05 respectively) both after one year and after 5 years.⁵

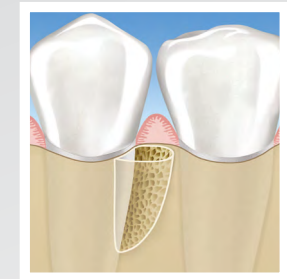Periodontal Defects



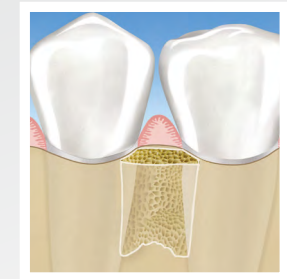One Wall Defect



Two Wall Defect



Three Wall Defect

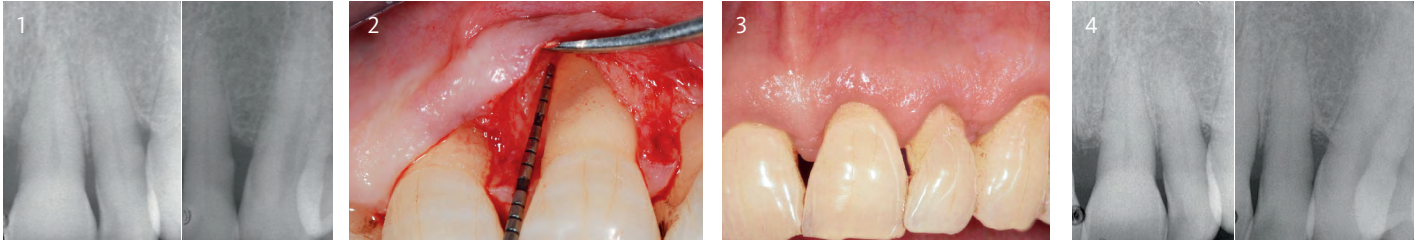


Interproximal Crater

CASE DOCUMENTATION

Periodontal Regenerative Surgery

Dr. Pierpaolo Cortellini (Florence, Italy)



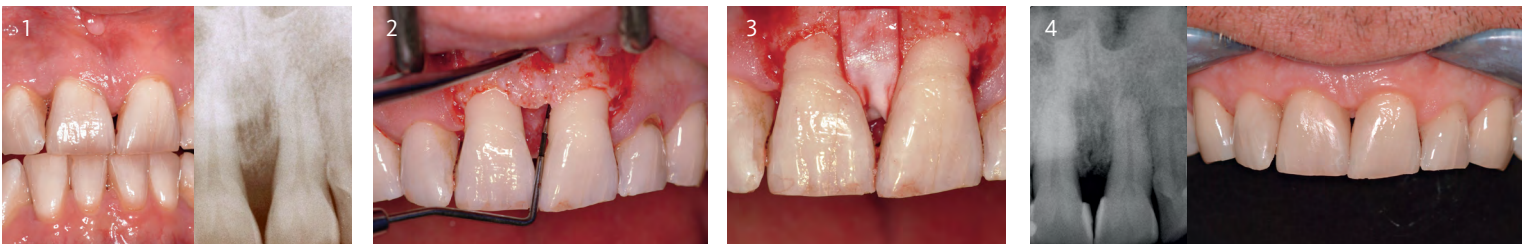
Objectives

- Resolution of deep pockets associated with deep intrabony defects and preservation of esthetics on upper incisors

- 1 Pre-operative radiographs showing the intrabony defects mesial to tooth 8 and distal to tooth 9
- 2 Intra-operative probing at tooth 8. Note the absence of the interdental bone peak between teeth 8 and 9 and the severe buccal dehiscence. Geistlich Bio-Oss® was used to prevent the postoperative shrinkage of the soft tissues
- 3 1 year post-op clinical situation showing healthy condition and a minimal gingival recession relative to baseline
- 4 1 year radiographs showing the resolution of the intrabony components of the defects

Intrabony 2-Wall Defect: Interproximal Crater

Dr. Frank Bröseler (Aachen, Germany)



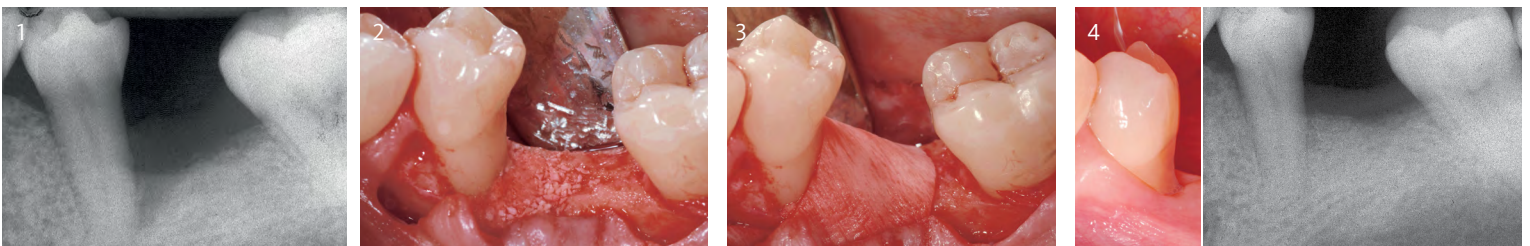
Objectives

- Functional and esthetic reconstruction in chronic periodontitis with deep intrabony defects.

- 1 Initial situation after anti-infective therapy. Radiographically, the intrabony defect cannot be represented in toto due to palatal bone plate
- 2 Intra-surgical situation after preparation of the mucoperiosteal full-thickness flap reveals deep osseous defect
- 3 The grafted site is covered with Geistlich Bio-Gide® Perio
- 4 4.5 years post-op radiograph showing sustained defect fill from Geistlich Bio-Oss Collagen®. Clinical situation at 7 years follow-up; note the naturally reformed papilla between the central incisors, and no gingival recession

3-Wall Defect: Rapid Progression of Lesion

Dr. Diego Capri (Bologna, Italy)



Objectives

- Regeneration of a 2 to 3 wall defect caused by a cemental tear

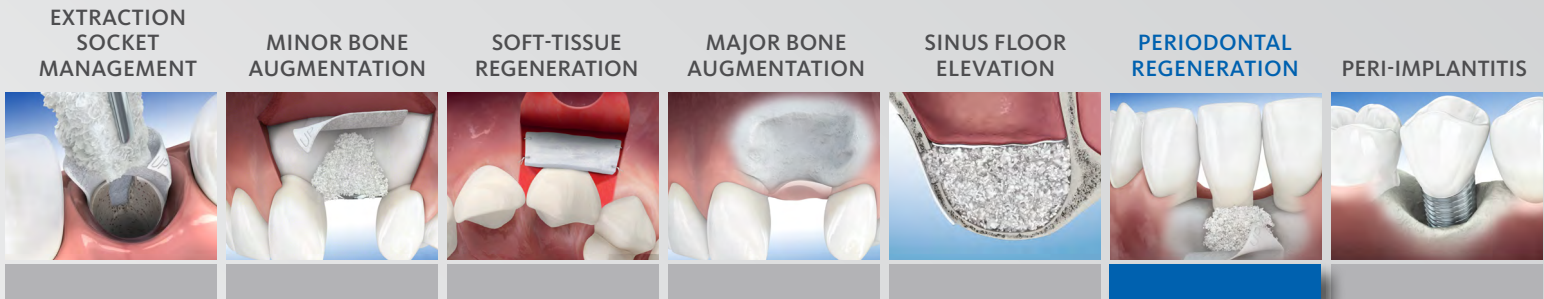
- 1 Diagnosis: Cemental tear – likely caused by a parafunctional habit overlapped to partial edentulism and malocclusion in the area.
- 2 The defect is filled with a mixture of autogenous bone and Geistlich Bio-Oss®
- 3 A trimmed Geistlich Bio-Gide® collagen membrane is positioned on the augmented area
- 4 Clinical situation 4 months after periodontal regenerative surgery a probing depth of 3 mm and a clinical attachment loss of 6 mm was measured distally. Intraoral radiographic aspect of the site showing the healing of the defect

For additional information on [Periodontal Regeneration](#), please visit the dental professional section of our website: www.geistlich-na.com

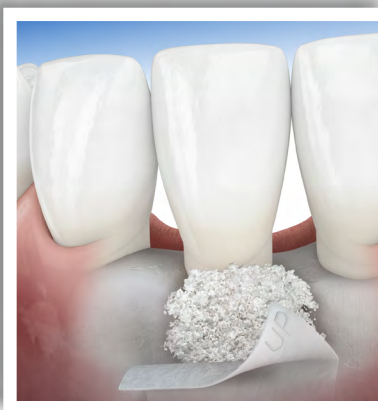THERAPEUTIC AREAS

At Geistlich Biomaterials, we are committed to developing treatments that are uniquely matched to the clinical situations you see every day. That's why we do more than bring you a family of products – we provide proven solutions in specific therapeutic areas.

The recommended Geistlich products below are the ideal biomaterials for use in **Periodontal Regeneration** procedures.



RECOMMENDED PRODUCTS FOR PERIODONTAL REGENERATION



| | | |
|------------------|--|---|
| BONE SUBSTITUTES | | Geistlich Bio-Oss Collagen® |
| MEMBRANES | | Geistlich Bio-Gide ® Perio |
| COMBINATION | | Geistlich Perio-System Combi-Pack |

The Ideal Geistlich Biomaterials for Periodontal Regeneration

When used in combination, these proven and reliable products provide a foundation for long-term clinical success in regenerative dentistry.

Geistlich Bio-Gide® ensures undisturbed bone regeneration and prevents soft-tissue ingrowth, while Geistlich Bio-Oss® or Geistlich Bio-Oss Collagen® provides a stable scaffold for bone formation leading to long-term volume preservation.

CAUTION: Federal law restricts these devices to sale by or on the order of a dentist or physician.

For information on indications, contraindications, precautions, and directions for use, please refer to the Geistlich Bio-Gide®, Geistlich Bio-Gide® Perio, Geistlich Bio-Oss® and Geistlich Bio-Oss Collagen® Instructions for Use at: www.geistlich-na.com/ifu

For additional information about Periodontal Regeneration please visit the dental professional section of our website: www.geistlich-na.com

¹ Lang NP et al., Ann Periodontol. 1997 Mar;2(1):343-356
² Schwarz F et al., Peri-implant Infection: Etiology, Diagnosis and Treatment. Quintessence Publishing. 2007. ISBN-13:978-3-938947-32-6
³ Rocuzzo M et al., Journal of Clinical Periodontology 2011; 38: 738–45
⁴ Roos-Jansaker A-M et al., Journal of Clinical Periodontology 2011; 38: 590–97
⁵ Froum SJ et al., International Journal of Periodontics and Restorative Dentistry 2012; 32: 11–20
⁶ Aghazadeh et al., J Clin Periodontol. 2012 Jul;39(7):666-73
⁷ Chan HL et al., J Periodontol. 2014 Aug;85(8):1027-41
⁸ Schwarz F et al., J Clin Periodontol. 2010 May;37(5):449-55
⁹ Schwarz F et al., J Clin Periodontol 2009; 36:807-814

Customer Care
Toll-free 855-799-5500

www.geistlich-na.com

Geistlich Pharma North America, Inc.
202 Carnegie Center • Princeton, NJ 08540