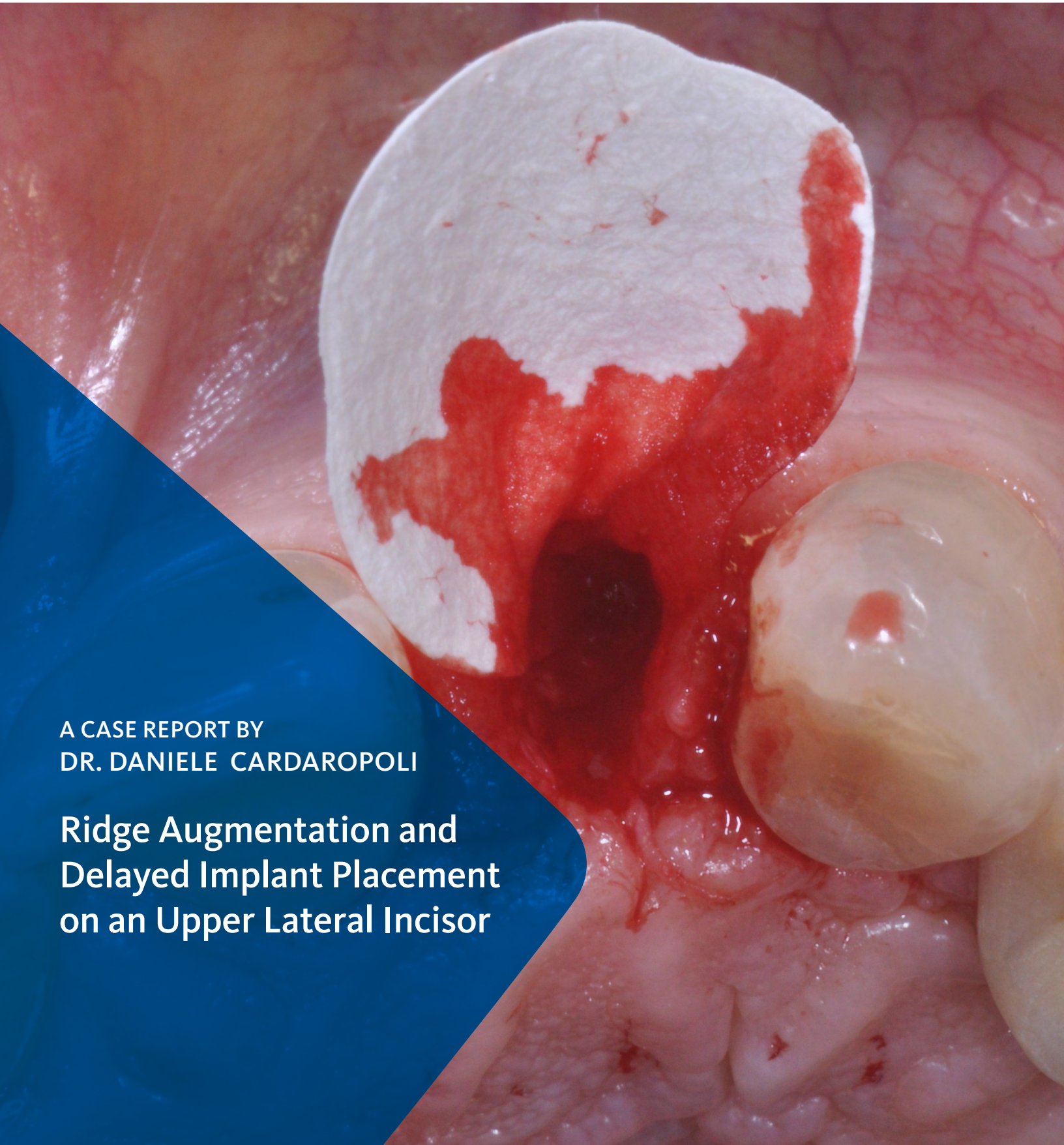
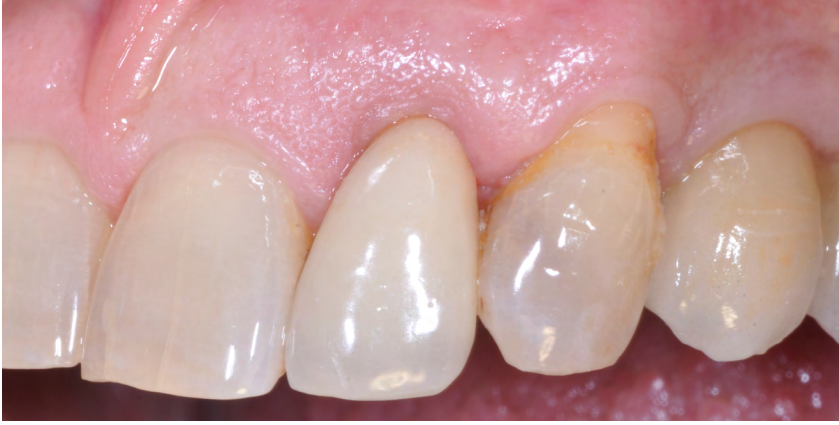


A CASE REPORT BY
DR. DANIELE CARDAROPOLI

Ridge Augmentation and Delayed Implant Placement on an Upper Lateral Incisor



▶ The Situation

An adult female patient presented with an endodontic/prosthetic failure on the maxillary left lateral incisor. The patient's request was to have a definitive implant-supported single crown. The clinical situation revealed recession of the free gingival margin, while the CBCT evaluation showed the missing buccal bone plate, which contra-indicated an immediate implant placement. The treatment plan included a staged approach with a ridge augmentation procedure at the time of tooth extraction, in order to recreate the buccal bone plate and reduce the gingival recession. By moving the free gingival margin, keratinized tissue was gained through an open-healing approach.

▶ The Risk Profile

Esthetic Risk Factors	Low Risk	Medium Risk	High Risk
Patient's health	Intact immune system	Light smoker	Impaired immune system
Patient's esthetic requirements	Low	Medium	High
Height of smile line	Low	Medium	High
Gingival biotype	Thick - "low scalloped"	Medium - "medium scalloped"	Thin - "high scalloped"
Shape of dental crowns	Rectangular		Triangular
Infection at implant site	None	Chronic	Acute
Bone height at adjacent tooth site	≤ 5 mm from contact point	5.5 - 6.5 mm from contact point	≥ 7 mm from contact point
Restorative status of adjacent tooth	Intact		Compromised
Width of tooth gap	1 tooth (≥ 7 mm)	1 tooth (≤ 7 mm)	2 teeth or more
Soft-tissue anatomy	Intact		Compromised
Bone anatomy of the alveolar ridge	No defect	Horizontal defect	Vertical defect

Note: The compromised soft-tissue created a high risk situation for esthetic failure and the need for a staged approach, in order to coronalize the free gingival margin

SPECIAL INTEREST

Bone and soft-tissue regeneration

“The patient had a failing crown with compromised soft-tissue and requested a single crown rehabilitation with improved esthetics.”

DANIELE CARDAROPOLI, DDS • TORINO, IT

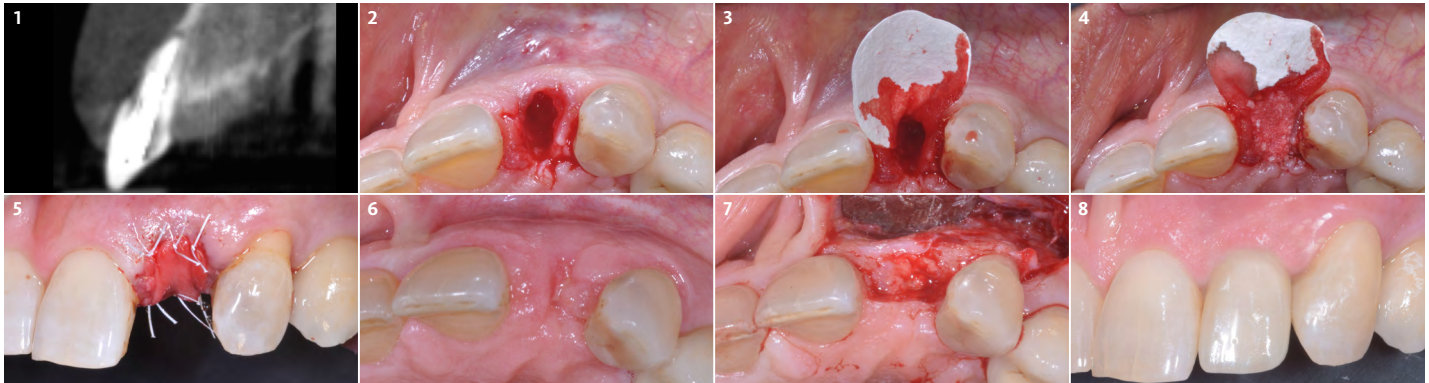
Periodontist - PROED, Institute for Professional Education in Dentistry, Torino

Doctor of Dentistry and Certificate in Periodontology from the University of Torino, Italy. Active member of the Italian Society of Periodontology, European Federation of Periodontology, Italian Academy of Osseointegration and Academy of Osseointegration. International member of the American Academy of Periodontology. Scientific Director of Institute for Professional Education in Dentistry (PROED), Torino. Member of the Editorial Board of The International Journal of Periodontics and Restorative Dentistry. Private practice in Torino, Italy.



▶ The Approach

The treatment goals were to improve the soft-tissue levels and regenerate the buccal bone plate. After performing a flapless extraction procedure, a specifically designed resorbable bilayer collagen membrane, Geistlich Bio-Gide® Shape, was inserted into the socket with the long wing in contact with the buccal surface and the smooth, compact upper layer facing outward. The alveolus was then grafted with Geistlich Bio-Oss Collagen®. The three smaller wings of the membrane were folded on top of the graft material and sutured to the surrounding soft-tissue, allowing for open-healing.



- 1 The cone beam image shows the missing bony buccal plate.
- 2 Clinical situation following a minimally invasive, flapless extraction approach.
- 3 Geistlich Bio-Gide® Shape is inserted into the socket, with the long wing in contact with the buccal surface in order to recreate the cortical bone.
- 4 The socket is carefully grafted with Geistlich Bio-Oss Collagen®.
- 5 The three remaining wings of Geistlich Bio-Gide® Shape are folded over the bone graft and gently secured inside the gingival sulcus. The membrane is then sutured to the surrounding soft-tissue with six single-interrupted sutures.
- 6 4 weeks post-operative view with an open-healing approach, showing a positive soft-tissue response.
- 7 After flap elevation at 4 months, the new buccal bone plate can be detected, together with a completely filled alveolus. An implant can now be easily inserted into a fully healed ridge.
- 8 Clinical image of the final ceramic crown. An esthetic improvement can be noted when compared with the baseline image. The free gingival margin has been shifted in a coronal direction.

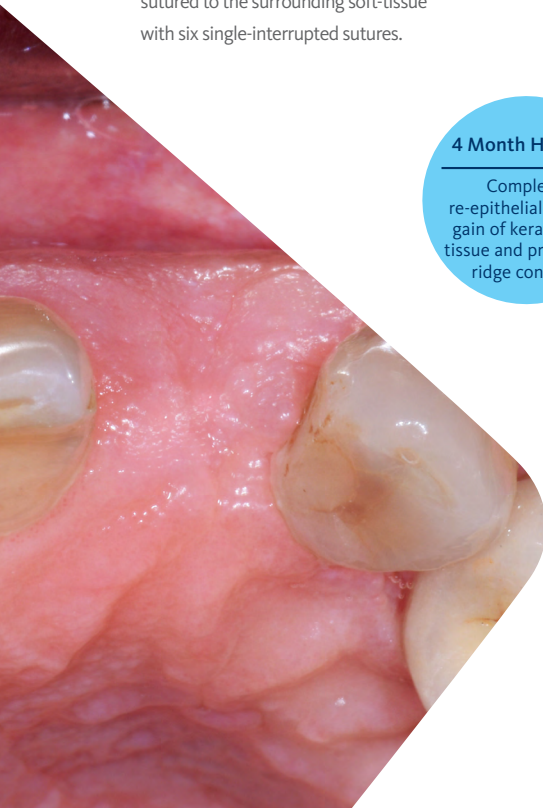
4 Month Healing
Complete re-epithelialization, gain of keratinized tissue and preserved ridge contour

“Prosthetically guided implant placement can be planned 4 months after the ridge augmentation procedure. The specifically designed Geistlich Bio-Gide® Shape was able to protect the Geistlich Bio-Oss Collagen®, not only in the coronal position but also aided in recreating the missing buccal bone.”

(See image to the left)

▶ The Outcome

This case demonstrates how it is possible to improve the clinical and esthetic situation that was presented at baseline. Despite missing the buccal bone plate and the recession of the free gingival margin, the ridge augmentation procedure performed with the combination of Geistlich Bio-Gide® Shape and Geistlich Bio-Oss Collagen® was able to create a positive volume of the ridge, allowing for a prosthetically guided implant placement.



Briefly Speaking

▶ Keys to Success

1. Minimally invasive, flapless extraction
2. Proper adaptation of the resorbable collagen membrane on the buccal surface of the alveolus
3. Immediately grafting the fresh extraction socket with a volume stable biomaterial
4. Protection of the bone substitute material with a resorbable collagen membrane
5. Open-healing capability of the resorbable collagen membrane
6. Prosthetically driven implant placement

▶ My Instruments

- A. Light straight elevator for the initial sindesmotomia extraction technique (Maxil® 70.H1521)
- B. Heavy elevator to dislocate the root and its conservative extraction capability (Maxil® 70.H1520)
- C. Cardaropoli Compactor instrument to adapt the resorbable collagen membrane (Maxil® 70.H1519)
- D. Cardaropoli Compactor instrument to compact the bone graft particles (Maxil® 70.H1519)
- E. PTFE non-resorbable suture to fix the membrane in place (PTFE 5/0 12mm 3/8, Omnia® 32.Z3151.00)
- F. Narrow diameter tapered implant (BLT Roxolid® SLActive® 3.3X14mm, Straumann®)

▶ My Biomaterials

Geistlich Bio-Gide® Shape has been specifically designed for ridge preservation. Due to its modified structure, it is firmer when dry to facilitate cutting of the material. Geistlich Bio-Oss Collagen® is comprised of the original Geistlich Bio-Oss® granules with 10% highly purified porcine collagen added for improved handling and adaptation of the material to the defect.



“The use of the Cardaropoli Compactor instrument helped to carefully adapt Geistlich Bio-Gide® Shape onto the inner buccal surface of the alveolus and to properly compact Geistlich Bio-Oss Collagen® inside the socket.”



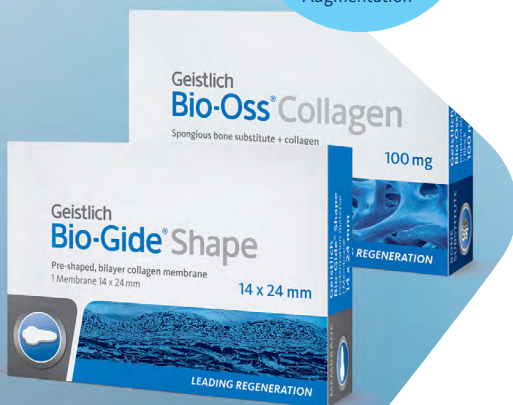Geistlich Bio-Gide® Shape is conveniently pre-cut for clinical use which reduces preparation time

Geistlich Bio-Gide® Shape & Geistlich Bio-Oss Collagen®
A winning combination for Minor Bone Augmentation

“Ridge augmentation combining the use of Geistlich Bio-Oss Collagen® and Geistlich Bio-Gide® Shape is a predictable minimally invasive regenerative procedure able to create sufficient ridge volume suitable for prosthetically driven implant placement.”



Geistlich Bio-Oss Collagen® provides the versatility needed to treat a wide range of defects



[▶ Click here to view the webinar](#)

Geistlich Pharma North America, Inc.

202 Carnegie Center

Princeton, NJ 08540

Customer Care Toll-free: 855-799-5500

info@geistlich-na.com

www.geistlich-na.com

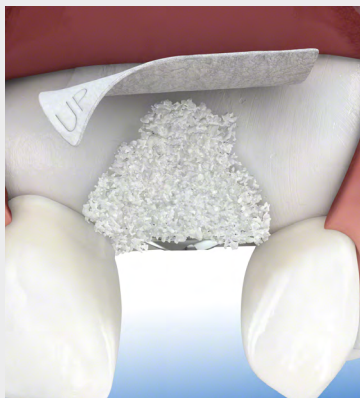ABOUT BIOBRIEF

We know that exposure to new or refined treatment approaches brings innovation to practice. Geistlich Biomaterials is pleased to introduce a periodic opportunity to get up close and personal with creative clinicians from around the world. Focused on peer-to-peer exchange, BIOBRIEF features clinically relevant cases and techniques in specific therapeutic areas – highlighted with valuable insights about materials and instrumentation, as well as KEYS TO SUCCESS.

Geistlich Biomaterials – bringing you *regeneration on time*.

► The Therapeutic Area

Geistlich biomaterials optimally compliments autogenous bone in Minor Bone Augmentation procedures. Due to its high resorption stability and osteoconductivity Geistlich Bio-Oss Collagen® protects human bone grafts against degradation, ensuring long-term volume preservation. When combined with Geistlich Bio-Gide® healing is undisturbed and provides significantly enhanced bone regeneration.



CAUTION: Federal law restricts these devices to sale by or on the order of a dentist or physician.

Indications:

Geistlich Bio-Oss Collagen® is indicated for the following uses: Augmentation or reconstructive treatment of the alveolar ridge; Filling of periodontal defects; Filling of defects after root resection, apicoectomy, and cystectomy; Filling of extraction sockets to enhance preservation of the alveolar ridge; Elevation of the maxillary sinus floor; Filling of periodontal defects in conjunction with products intended for Guided Tissue Regeneration (GTR) and Guided Bone Regeneration (GBR); and Filling of peri-implant defects in conjunction with products intended for GBR.

Warnings:

Possible complications which may occur with any surgery include swelling at the surgical site, flap sloughing, bleeding, local inflammation, bone loss, infection or pain. As Geistlich Bio-Oss Collagen® contains collagen, in very rare circumstances cases of allergic reactions may occur.

Indications:

Geistlich Bio-Gide® Shape is indicated for the following uses: Augmentation around implants placed in immediate or delayed extraction sockets; localized ridge augmentation for later implantation; alveolar ridge reconstruction for prosthetic treatment; filling of bone defects after root resection; cystectomy and removal of retained teeth and guided bone regeneration in dehiscence defects.

Warnings:

As Geistlich Bio-Gide® Shape is a collagen product allergic reactions may not be totally excluded. Possible complications which may occur with any surgery include swelling at the surgical site, flap sloughing, bleeding, dehiscence, hematoma, increased sensitivity and pain, bone loss, redness and local inflammation.

For more information on contraindications, precautions, and directions for use, please refer to the Geistlich Bio-Oss Collagen® and Geistlich BioGide® Shape Instructions for Use at: www.geistlich-na.com/ifu