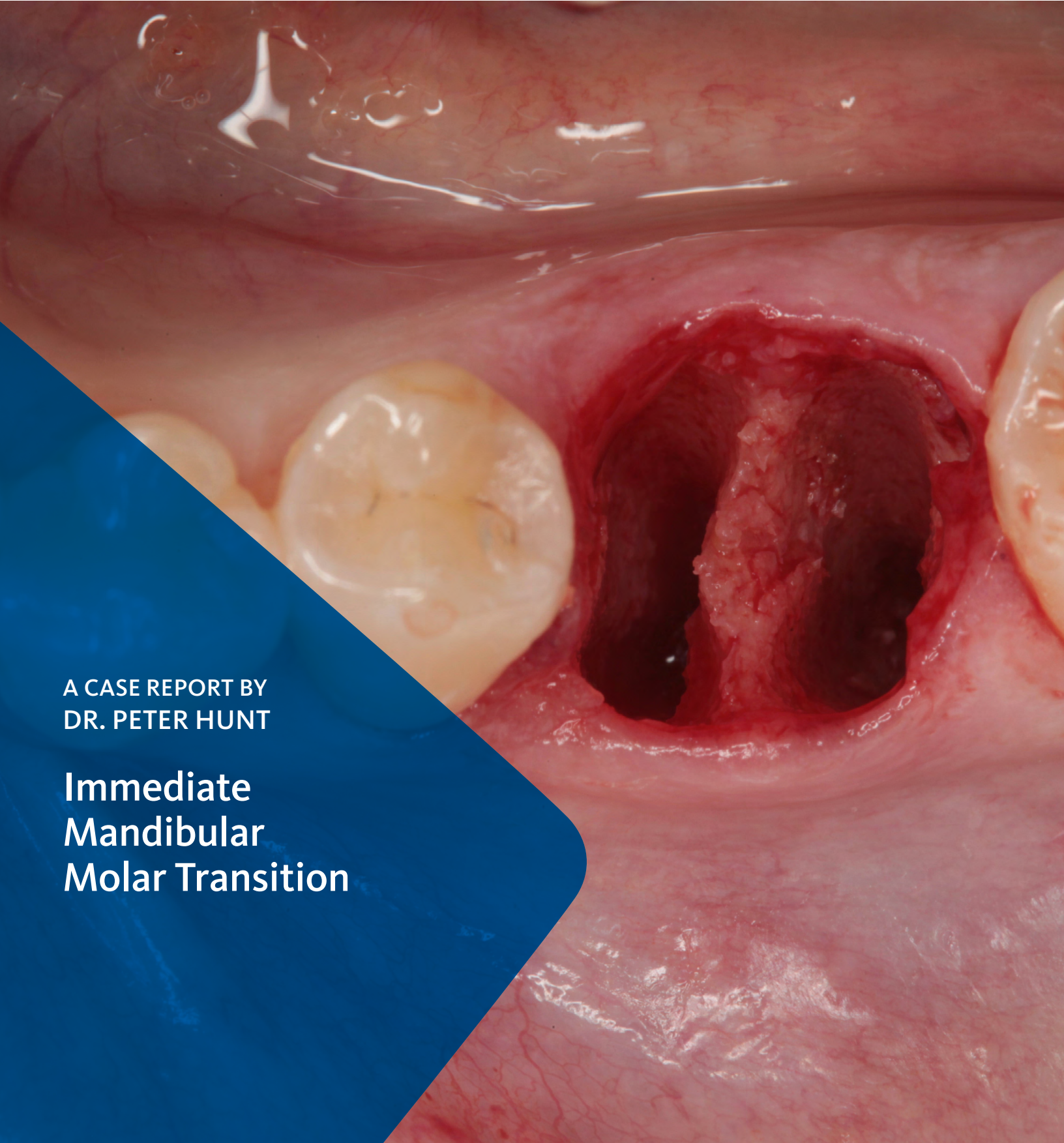
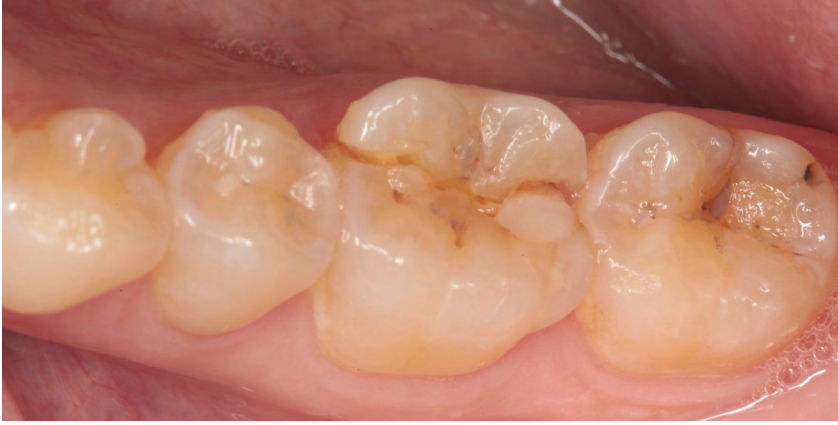

A CASE REPORT BY
DR. PETER HUNT

Immediate Mandibular Molar Transition





▶ The Situation

The case here is typical enough, a failing mandibular molar with a vertical sub-osseous fracture. Traditionally, the replacement process can take three or more surgical exposures (extraction and regeneration), (implant placement), (second stage exposure) and more than a year of therapy.

▶ The Risk Profile

Esthetic Risk Factors	Low Risk	Medium Risk	High Risk
Patient's health	Intact immune system	Light smoker	Impaired immune system
Patient's esthetic requirements	Low	Medium	High
Height of smile line	Low	Medium	High
Gingival biotype	Thick - "low scalloped"	Medium - "medium scalloped"	Thin - "high scalloped"
Shape of dental crowns	Rectangular		Triangular
Infection at implant site	None	Chronic	Acute
Bone height at adjacent tooth site	≤ 5 mm from contact point	5.5 - 6.5 mm from contact point	≥ 7 mm from contact point
Restorative status of adjacent tooth	Intact		Compromised
Width of tooth gap	1 tooth (≥ 7 mm)	1 tooth (≤ 7 mm)	2 teeth or more
Soft-tissue anatomy	Intact		Compromised
Bone anatomy of the alveolar ridge	No defect	Horizontal defect	Vertical defect

SPECIAL INTEREST

Augmentation in Implantology

“The patient desires an implant placement for a fractured mandibular molar, as fast as possible.”

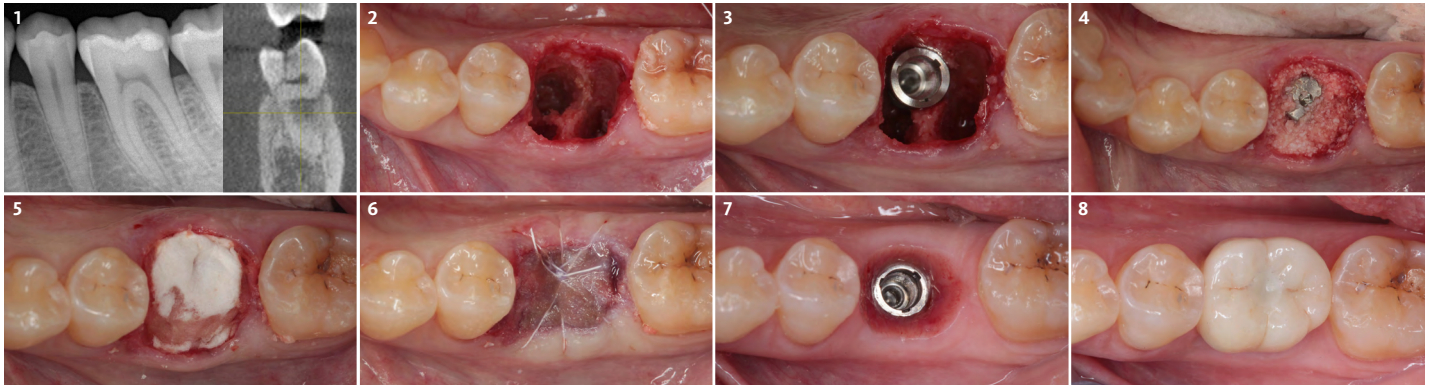
PETER HUNT, BDS, MSc, LDSRCS Eng • PHILADELPHIA, PA
Periodontist - University of Pennsylvania

After graduate training on an Annenberg Fellowship at the University of Pennsylvania, Dr. Hunt helped start up the University of the Western Cape Dental School in Cape Town, South Africa. He returned to the University of Pennsylvania where in time he became Clinical Professor of Periodontics. Later he helped start up Nova Southeastern's Dental School where he was Professor of Restorative Dentistry, Post Graduate Director and Director of Implantology. He has had a private practice in Philadelphia focusing on implant and rehabilitation dentistry since 1981.



▶ The Approach

Immediate molar replacement requires atraumatic removal of the fractured tooth, careful socket debridement and development of a channel for an ideally positioned implant. The implant then needs to be placed down in the bone channel with the implant platform positioned just below the socket walls. It needs to be stable. Channel deficiency augmentation is achieved with Geistlich Bio-Oss Collagen® which is covered with a collagen matrix, Geistlich Mucograft® with the edges tucked under the gingival margins and sealed over with tissue glue.



- 1 A pre-operative radiograph and CBCT showing the cross-section of the involved tooth.
- 2 An implant site was developed by placing a pilot drill down the mesial root space, then uprighting it. This was continued up through the drill sequence. The mesial radicular septum is moved in the process.
- 3 A Camlog® 5.0 x 11 mm implant was placed with the platform set just down below the bone height of the socket walls.
- 4 After placing a 4.0 mm height cylindrical gingiva former in the implant, 250 mg of Geistlich Bio-Oss Collagen® was packed down in the socket around the implant.
- 5 Geistlich Mucograft® was adapted to the region then tucked down under the gingival margin.
- 6 The gingival margins were adapted and closed together with 4.0 teflon sutures (Cytoplast™, Osteogenics). The region was then covered with Geistlich - PeriAcryl® 90 Oral Tissue Adhesive.
- 7 4 months later following Emergence Profile Development.
- 8 An occlusal view of the final one-piece, screw-retained zirconia crown restoration based on a Camlog® Titanium Base Abutment.

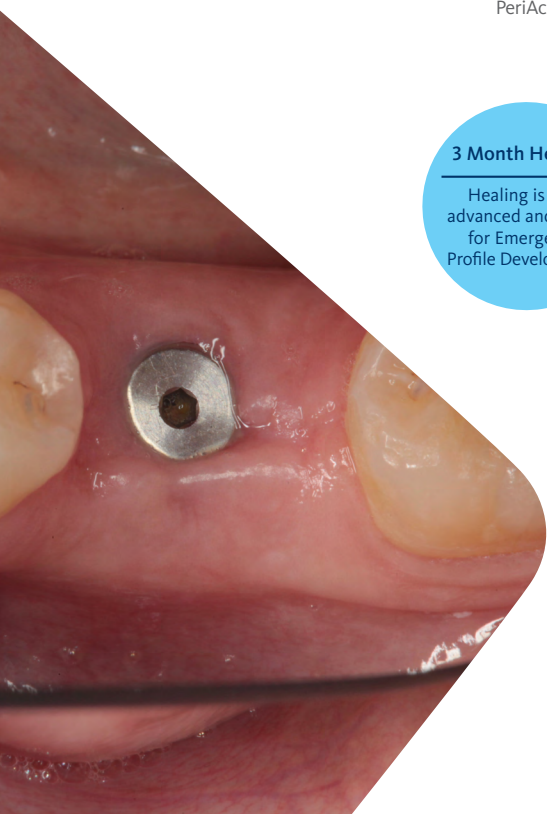
3 Month Healing

Healing is well advanced and ready for Emergence Profile Development

“After 3 months of healing, the top of the gingiva former is exposed and the situation is ready for Emergence Profile Development. This is quite standard.”

▶ The Outcome

This single stage replacement protocol has proven to be simple, safe and highly effective providing the socket is fully degranulated and the implant is stable and not loaded in the early healing stages. It works well when a gingiva former is immediately placed into the implant instead of a cover screw, Geistlich Bio-Oss Collagen® is packed around the implant to fill the residual socket, then covered with a Geistlich Mucograft® and sutured. There is no need for flap advancement to cover over the socket.



Briefly Speaking

▶ Keys to Success

1. Atraumatic extraction
2. Thorough degranulation and debridement of the residual socket
3. Adequate stability for the implant
4. Placement of the implant platform down just below the walls of the socket
5. Placing a 4.0 mm height gingiva former instead of a cover screw
6. Augmenting with Geistlich Bio-Oss Collagen® and covering with Geistlich Mucograft®
7. No loading of the implant in the early healing stages

▶ My Instruments

- A. EVO 15 electric micromotor handpiece for sectioning the tooth (Bien Air)
- B. Ultrasonic periotome tips to loosen, flush and elevate out root tips (Mectron)
- C. OM1 hand held periotome to tweak out root fragments (Zoll Dental)
- D. Hand held curettes CL866 and excavators SPR 1/2 to degranulate and debride the socket (Hu-Friedy)
- E. iChiropro Implantology System for precision implant channel preparation (Bien Air)
- F. #4 Molt Excavator (Zoll Dental)

▶ My Biomaterials

- Geistlich Bio-Oss Collagen® has excellent handling and enhanced healing characteristics due to the addition of 10% collagen to the original Geistlich Bio-Oss® granules. Geistlich Mucograft® is specifically designed for soft-tissue regeneration. The matrix properties provides closure and contains the bone graft while allowing open healing as well as the ingrowth of soft-tissue cells.



“The Ultrasonic Peritome tips have made it significantly easier to remove teeth atraumatically in my practice.”

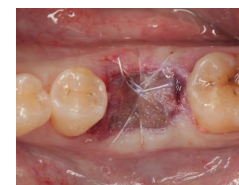Geistlich
Bio-Oss Collagen®
& Geistlich Mucograft®

A good combination
for Extraction Socket
Management



Geistlich Mucograft® is measured, cut to size and placed directly onto the defect

“This procedure really just merges a socket regeneration procedure with implant placement. It’s a simple and effective procedure which has now become quite standard for us.”



Geistlich Mucograft® in place, adapted to the defect and completely saturated



Click here to view the webinar

Geistlich Pharma North America, Inc.

202 Carnegie Center
Princeton, NJ 08540
Customer Care Toll-free: 855-799-5500
info@geistlich-na.com
www.geistlich-na.com

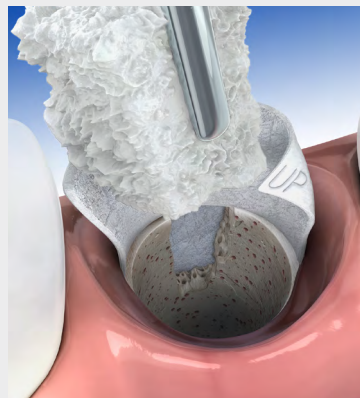
ABOUT BIOBRIEF

We know that exposure to new or refined treatment approaches brings innovation to practice. Geistlich Biomaterials is pleased to introduce a periodic opportunity to get up close and personal with creative clinicians from around the world. Focused on peer-to-peer exchange, BIOBRIEF features clinically relevant cases and techniques in specific therapeutic areas – highlighted with valuable insights about materials and instrumentation, as well as KEYS TO SUCCESS.

Geistlich Biomaterials – bringing you *regeneration on time*.

► The Therapeutic Area

It is well documented that Geistlich biomaterials can significantly reduce the ridge resorption that typically follows dental extractions. Procedures like the one shown here by Dr. Hunt make it clear that in many cases it is possible to place implants into extraction sockets before augmenting with Geistlich biomaterials. This reduces surgical interventions, speeds therapy and minimizes ridge collapse.



CAUTION: Federal law restricts these devices to sale by or on the order of a dentist or physician.

Indications:

Geistlich Bio-Oss Collagen® is indicated for the following uses: Augmentation or reconstructive treatment of the alveolar ridge; Filling of periodontal defects; Filling of defects after root resection, apicoectomy, and cystectomy; Filling of extraction sockets to enhance preservation of the alveolar ridge; Elevation of the maxillary sinus floor; Filling of periodontal defects in conjunction with products intended for Guided Tissue Regeneration (GTR) and Guided Bone Regeneration (GBR); and Filling of peri-implant defects in conjunction with products intended for GBR.

Warnings:

Possible complications which may occur with any surgery include swelling at the surgical site, flap sloughing, bleeding, local inflammation, bone loss, infection or pain. As Geistlich Bio-Oss Collagen® contains collagen, in very rare circumstances cases of allergic reactions may occur.

Indications:

Geistlich Mucograft® is indicated for the following uses: Covering of implants placed in immediate or delayed extraction sockets, localized gingival augmentation to increase keratinized tissue (KT) around teeth and implants, alveolar ridge reconstruction for prosthetic treatment, recession defects for root coverage.

Warnings:

As Geistlich Mucograft® is a collagen product allergic reactions may not be totally excluded. Possible complications which may occur with any surgery include swelling at the surgical site, flap sloughing, bleeding dehiscence, hematoma, increased sensitivity and pain, bone loss, redness and local inflammation.

For more information on contraindications, precautions, and directions for use, please refer to the Geistlich Bio-Oss Collagen® and Geistlich Mucograft® Instructions for Use at: www.geistlich-na.com/ifu