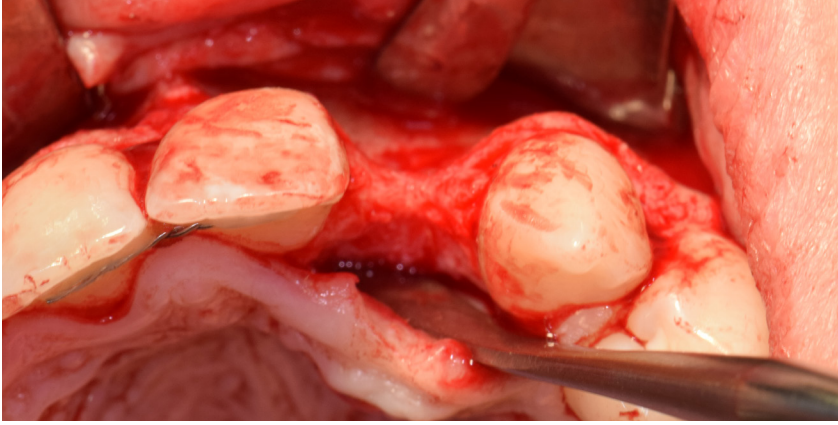


An intraoperative photograph showing a surgical site in the maxilla. The image displays the gingival tissue, underlying bone, and a dental implant or graft site. A blue diagonal overlay is present in the bottom-left corner, containing text.

A CASE REPORT BY  
DR. RICHARD E. BAUER

## Ramal Bone Graft for Congenitally Missing Maxillary Lateral Incisor



## ▶ The Situation

An 18 year old female presented with a congenitally missing tooth #10. The patient previously sought care by another provider and had undergone guided bone regeneration with allograft and subsequent implant placement with additional grafting at the time of implant placement. The implant ultimately failed and was removed prior to my initial consultation. An examination revealed maximal incisal opening, within normal limits, missing #10 with 6 mm ridge width. In addition there was a significant palpable cleft-like depression on the facial aspect of the ridge, adequate attached tissue but reduced vertical height in relation to adjacent dentition and attached tissue. Previous surgeries resulted in extensive fibrous tissue with scarring at site #10. Plan: A ramal bone graft is indicated at the congenitally missing site #10 with Geistlich Bio-Oss® and Geistlich Mucograft® matrix utilized for ridge augmentation prior to secondary implant placement.

## ▶ The Risk Profile

Esthetic Risk Factors	Low Risk	Medium Risk	High Risk
Patient's health	Intact immune system	Light smoker	Impaired immune system
Patient's esthetic requirements	Low	Medium	High
Height of smile line	Low	Medium	High
Gingival biotype	Thick - "low scalloped"	Medium - "medium scalloped"	Thin - "high scalloped"
Shape of dental crowns	Rectangular		Triangular
Infection at implant site	None	Chronic	Acute
Bone height at adjacent tooth site	≤ 5 mm from contact point	5.5 - 6.5 mm from contact point	≥ 7 mm from contact point
Restorative status of adjacent tooth	Intact		Compromised
Width of tooth gap	1 tooth (≥ 7 mm)	1 tooth (≤ 7 mm)	2 teeth or more
Soft-tissue anatomy	Intact		Compromised
Bone anatomy of the alveolar ridge	No defect	Horizontal defect	Vertical defect

**SPECIAL INTEREST**

Regenerative medicine for hard and soft-tissue reconstruction

“This is a young patient with a congenitally missing incisor that has high esthetic concerns and has had multiple failed surgical attempts that is now presenting for definitive management.”

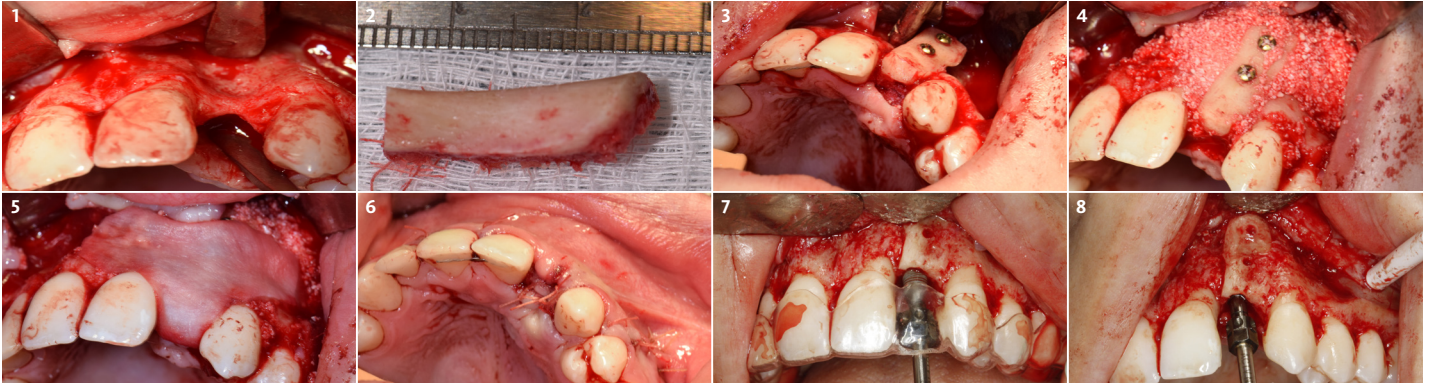
**RICHARD E. BAUER, III, DMD, MD • PITTSBURGH, PA**  
Oral and Maxillofacial Surgeon - University of Pittsburgh

Dr. Richard E. Bauer, III, DMD, MD is a graduate of the University of Pittsburgh Schools of Dental Medicine and Medicine. Dr. Bauer completed his residency training in Oral and Maxillofacial Surgery at the University of Pittsburgh Medical Center. Dr. Bauer has served on multiple committees for the American Association of Oral and Maxillofacial Surgery (AAOMS). He is a full-time faculty member and Residency Program Director at the University of Pittsburgh in the department of Oral and Maxillofacial Surgery and his practice is focused on dental implants and corrective jaw surgery. He has been active in research with focus on bone regeneration and virtual applications for computer assisted planning and surgery.



## ▶ The Approach

The goals for this patient are to reconstruct the osseous foundation and provide a matrix for improvement with the overlying soft-tissue. Specifically, a coordinated multidisciplinary plan was established with the restoring dentist, periodontist and oral surgeon. A plan for idealized anterior cosmetic prosthetic restoration was established. Sequencing of treatment was established. Surgical phase one included a ramal bone graft to site #10 and Essix type temporary prosthesis for immediate post-operative phase followed by a temporary Maryland bridge. Surgical phase two included implant placement and simultaneous crown lengthening and osteoplasty. This stage was done with immediate provisionalization.



- 1 A flap has been raised and reveals a significant facial and palatal defect at congenitally missing site #10.
- 2 Harvested ramal graft. Slightly over-sized to allow for mitring and harvest of particulate autograft with a bone trap on the suction.
- 3 Onlay graft now secured with two fixation screws (Stryker) with a lag screw technique. Geistlich Bio-Oss Collagen® has been placed on the palatal aspect of site #10.
- 4 Combination of a fixated onlay graft with Geistlich Bio-Oss®/autograft particulate graft at the periphery and over the facial plate of the adjacent dentition.
- 5 Geistlich Mucograft® matrix placed over facial augmentation of the adjacent dentition and ridge crest of the augmented site.
- 6 Closure following ramal grafting and Geistlich Mucograft® matrix application.
- 7 Implant placement with static guide and dental implant hand driver.
- 8 Implant placement with slight subcrestal placement of the platform just prior to osteoplasty by the periodontist.

### 3 Month Healing

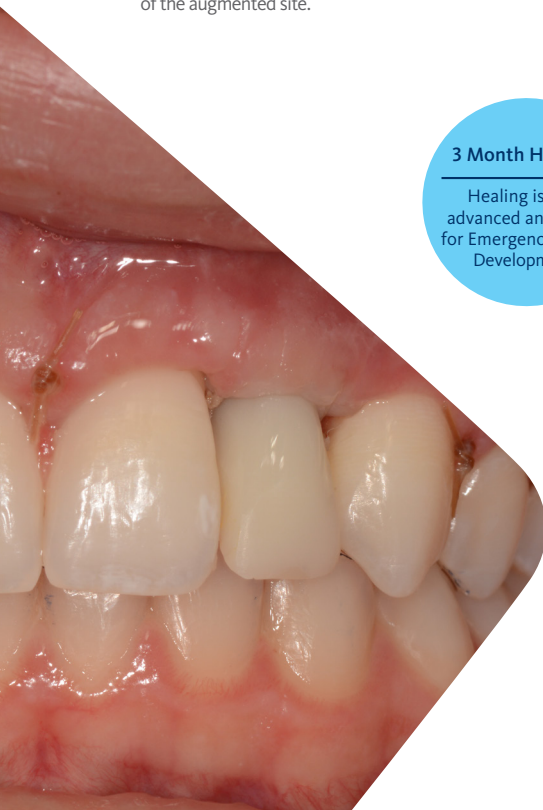Healing is well advanced and ready for Emergence Profile Development

“Immediate provisional in place 2 days after implant placement and osteoplasty. There has been significant gain in bony architecture and development of soft-tissue contours at a site that was extremely deficient of structure to begin with.”

(See image to the left)

## ▶ The Outcome

This case was dependent upon adequate hard-tissue reconstruction combined with soft-tissue manipulation to eliminate scar tissue and provide esthetic re-contouring. Obtaining an adequate autogenous graft combined with Geistlich Bio-Oss® at the periphery of the onlay graft is essential for anterior-posterior and vertical augmentation. Utilizing a Geistlich Mucograft® matrix at the ridge crest to help contain the particulate graft and improve the soft-tissue profile for subsequent immediate provisionalization and re-contouring of the surrounding soft-tissue played a significant role in the esthetic success.



# Briefly Speaking

## ▶ Keys to Success

1. Identifying a problem list and potential pitfalls at the treatment planning stage.
2. Having a group of professional colleagues to execute complicated cases as a team. Each having skill sets that they are specialized in and can provide reliable outcomes.
3. Slightly larger autogenous block graft than what is necessary to allow for mitering and fixating. Fixating the onlay graft with a lag screw technique to eliminate micromotion across the graft.
4. Particulate grafting the periphery of the onlay graft. Geistlich Bio-Oss® combined with autogenous bone harvested with a bone trap while mitering the autogenous block.
5. Soft-tissue matrix (Geistlich Mucograft®) to maximize soft-tissue availability and re-contouring during crown lengthening, osteoplasty and immediate implant provisionalization.

## ▶ My Biomaterials

Geistlich Bio-Oss® is a biocompatible porous bovine bone mineral substitute. Due to its structure, it is physically and chemically comparable to the mineralized matrix of human bone. Geistlich Mucograft® is specifically designed for soft-tissue regeneration. The matrix properties provides closure and contains the bone graft while allowing open healing as well as the ingrowth of soft-tissue cells.

Geistlich Bio-Oss®  
Geistlich Bio-Oss Collagen®  
& Geistlich Mucograft®

A good combination for Major Bone Augmentation



## ▶ My Instruments

- A. Piezo Surgical Unit for ramal graft harvest (Piezosurgery®)
- B. Notched Ramus Retractor to gain adequate visualization while harvesting the autogenous block graft (KLS Martin)
- C. Osseous Coagulum Trap and filter basket to capture autogenous bone while mitering the autogenous block (Salvin® Dental Specialties)
- D. Craniomaxillofacial Fixation Screw(s) and utilizing a lag screw technique to secure the onlay graft (Stryker®)
- E. Sharp Curved Iris Scissor for periosteal release for tension free closure (Hu-Friedy®)
- F. Straight Surgical Hand Driver for implant delivery/insertion in the maxillary anterior sites (Nobel Biocare®)



“The importance of a quality fixation screw/system cannot be understated. Securing the graft and subsequently being able to retrieve the screw(s) without stripping or fracturing the screw head is imperative to ideal implant placement.”



Before application Geistlich Bio-Oss® is mixed with autogenous blood or saline solution



Geistlich Mucograft® is measured, cut to size and placed directly onto the defect

“Identify the problem, establish a sequenced plan and execute with equal attention to hard and soft-tissue augmentation and manipulation.”



[Click here to view the webinar](#)

**Geistlich Pharma North America, Inc.**

202 Carnegie Center  
Princeton, NJ 08540  
Customer Care Toll-free: 855-799-5500  
info@geistlich-na.com  
www.geistlich-na.com

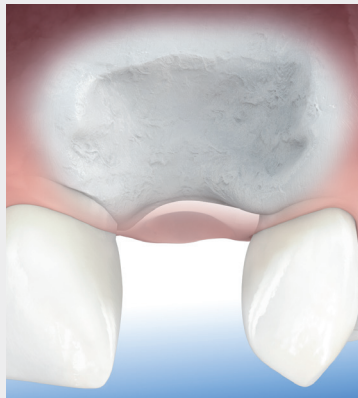## ABOUT BIOBRIEF

We know that exposure to new or refined treatment approaches brings innovation to practice. Geistlich Biomaterials is pleased to introduce a periodic opportunity to get up close and personal with creative clinicians from around the world. Focused on peer-to-peer exchange, BIOBRIEF features clinically relevant cases and techniques in specific therapeutic areas – highlighted with valuable insights about materials and instrumentation, as well as KEYS TO SUCCESS.

Geistlich Biomaterials – bringing you *regeneration on time*.

## ► The Therapeutic Area

Autogenous bone grafts are subject to a certain amount of resorption, Geistlich biomaterials optimally compliments autogenous bone in Major Bone Augmentation procedures. Due to its high resorption stability and osteoconductivity Geistlich Bio-Oss® protects human bone grafts against degradation, ensuring long-term volume preservation.



**CAUTION:** Federal law restricts these devices to sale by or on the order of a dentist or physician.

**Indications:**

Geistlich Bio-Oss® and Geistlich Bio-Oss Collagen® are indicated for the following uses: Augmentation or reconstructive treatment of the alveolar ridge; Filling of periodontal defects; Filling of defects after root resection, apicoectomy, and cystectomy; Filling of extraction sockets to enhance preservation of the alveolar ridge; Elevation of the maxillary sinus floor; Filling of periodontal defects in conjunction with products intended for Guided Tissue Regeneration (GTR) and Guided Bone Regeneration (GBR); and Filling of peri-implant defects in conjunction with products intended for GBR.

**Warnings:**

Possible complications which may occur with any surgery include swelling at the surgical site, flap sloughing, bleeding, local inflammation, bone loss, infection or pain. As Geistlich Bio-Oss Collagen® contains collagen, in very rare circumstances cases of allergic reactions may occur.

**Indications:**

Geistlich Mucograft® is indicated for the following uses: Covering of implants placed in immediate or delayed extraction sockets, localized gingival augmentation to increase keratinized tissue (KT) around teeth and implants, alveolar ridge reconstruction for prosthetic treatment, recession defects for root coverage.

**Warnings:**

As Geistlich Mucograft® is a collagen product allergic reactions may not be totally excluded. Possible complications which may occur with any surgery include swelling at the surgical site, flap sloughing, bleeding dehiscence, hematoma, increased sensitivity and pain, bone loss, redness and local inflammation.

For more information on contraindications, precautions, and directions for use, please refer to the Geistlich Bio-Oss®, Geistlich Bio-Oss Collagen® and Geistlich Mucograft® Instructions for Use at: [www.geistlich-na.com/ifu](http://www.geistlich-na.com/ifu)